

GUIDELINES FOR HANDLING PEDIATRIC LUNG BIOPSIES

1. SITE AND SIZE OF BIOPSY:

For focal disease, the biopsy should be taken from a **region of involvement**.

For diffuse lung disease, the biopsy should be taken from **any site, except the tip of the right middle lobe or the tip of the lingula**. These areas tend to show disproportionately severe changes and may lead to a faulty impression of degree of injury.

Recommended size is approximately **2-3 cm wide and at least 1 cm deep** for open or thoracoscopic wedge lung biopsy. This allows adequate quantity of tissue for special studies and provides adequate depth of biopsy for assessment of airways.

2. SPECIMEN HANDLING IN PATHOLOGY:

SPECIAL STUDIES:

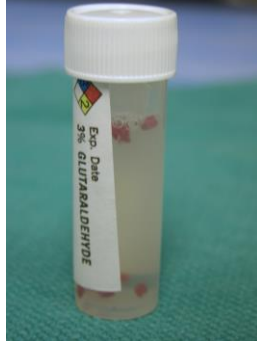
While the specimen is fresh, portions of the biopsy should be submitted for special studies from the lateral edges of the biopsy, as indicated below. If there is insufficient material for all studies, they should be prioritized according to clinical indications.

1. **Microbiology cultures (sterile)** – bacterial, viral, fungal and/or acid fast
2. **Rapid diagnosis of opportunistic infection** – 6 total touch imprints (3 air-dried, 3 alcohol-fixed) for special stains
3. **Electron microscopy** – fixed in glutaraldehyde – few small pieces (1 mm each)
4. **Molecular diagnostics** (viral, genetic) – snap frozen in a cryovial
5. **Immunofluorescence** – inflate with OCT/sucrose* and snap freeze in a cryomold with OCT (see technique below).

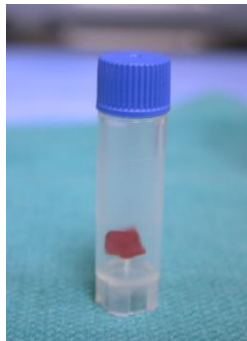
Cultures



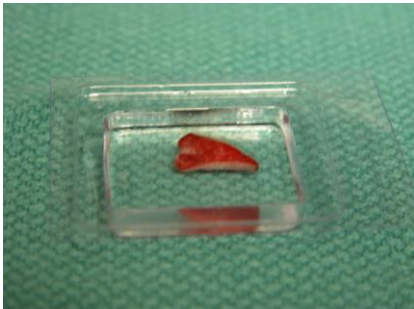EM



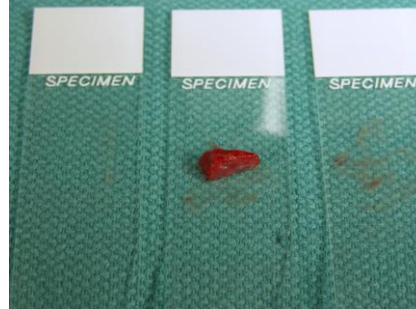Snap freeze (PCR)



Snap freeze in OCT (IF)



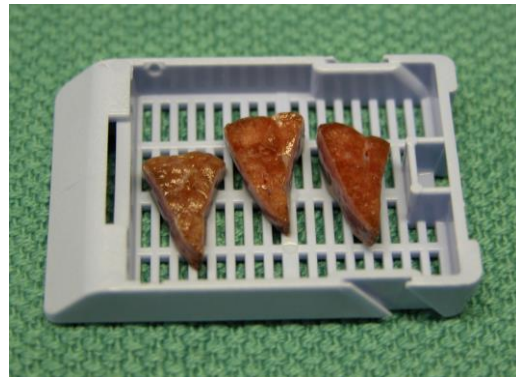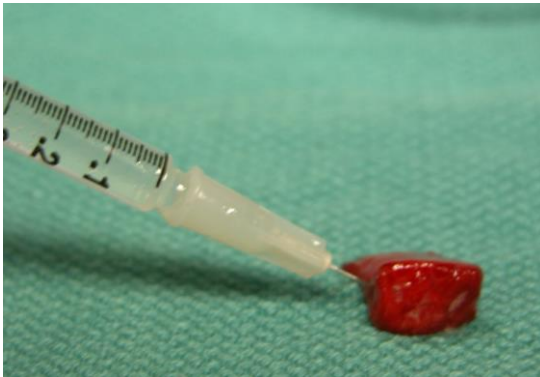Touch preps (3 EtOH fixed, 3 air dried)



* **Technical Note: Freezing lung tissue in OCT.** Inject a section of lung tissue with OCT/sucrose mixture (equal parts OCT cryomatrix and 0.5 molar sucrose) using a tuberculin syringe. The sucrose is used to decrease the viscosity of the OCT and allows injection and expansion of the lung tissue prior to freezing. OCT/sucrose can be kept in the refrigerator in the grossing area and should be warmed to room temperature before use. Draw up the OCT/sucrose mixture into a tuberculin syringe through the hub (with the needle removed). Replace the needle and gently inflate the tissue section. Placed the inflated section in a cryomold , embed it in OCT (not OCT/sucrose mixture), and snap freeze in liquid nitrogen.

HISTOPATHOLOGY:

The remaining mid-portion of the lung biopsy should be fixed by inflation with formalin. Remove the staple line. Fill a tuberculin syringe (or other fine needle and syringe) with formalin and gently inflate the biopsy by puncturing the pleura with the needle and using gentle pressure to inflate the lung tissue. Some fluid will leak from the surfaces, but the tissue will visibly distend and retain most of the formalin. Reposition the needle and continue injecting until the tissue appears maximally expanded. Place it in a container with additional formalin and let it fix for approximately 15-20 minutes before sectioning and submitting cassettes for histology. Section the tissue perpendicular to the resection margin, such that each plane of section is wedge-shaped, including the central flat edge and the peripheral angle.



3. **PEDIATRIC LUNG PATHOLOGY CONSULTATION SERVICE:**

Please send **1 H&E recut slide** of each block and at least **6 unstained slides** (or a representative block) to the following address:

Megan K. Dishop MD
Division Chief, Pathology and Laboratory Medicine
Phoenix Children's Hospital
1919 E. Thomas Rd, Main Tower
Phoenix, Arizona 85016
Ph: 602-933-1283
Fax: 602-933-1284
Email: mdishop@phoenixchildrens.com

Also include a copy of the pathology report and any relevant clinical information (clinical summary, H&P, Pulmonary consult note, Diagnostic imaging/Chest CT results, etc.). Frozen and EM tissue may be retained until requested for further diagnostic evaluation.

rev: mkd 05/31/18